


## Case Report

# Conservative Treatment of the Fifth Metatarsal Bone Fractures in Professional Football Players Using Platelet-Rich Plasma

Eduard Bezuglov, MD,  
Andrey Zholinsky, MD, Gleb Chernov, MD,  
Vladimir Khaitin, MD,  
Evgeniy Goncharov, MD,  
Zbigniew Waśkiewicz, PhD,  
Ekaterina Barskova, MD,  
and Artemii Lazarev, MD, 

**Abstract:** *Injuries of the metatarsal bones in football are relatively rare and in most cases are localized in the fifth metatarsal. The gold standard of the diagnosis of fractures in this area can be X-rays, which in most cases allows verifying the diagnosis. The treatment tactics depend on the localization of the fracture according to Lawrence and Botte's classification: 3 zones of localization are distinguished. Fractures located in zones 2 and 3 belong to a high-risk group due to delayed consolidation and nonunion and therefore athletes are most often treated with osteosynthesis using intramedullary screws. The minimal recovery time for this type of treatment is at least 8 weeks. This report describes 7 cases of the fifth metatarsal bone fractures, located in zones 2 and 3 in professional football players who were treated with an immobilization boot, cryotherapy, nutritional supplements of calcium and vitamin D, and local*

*injections of platelet-rich plasma, which contains numerous growth factors. The deadline for returning to regular training activities was 43 to 50 days, and there was no relapse of damage within 6 months of follow-up.*

**Levels of Evidence:** *Level of evidence 4: case report study*

**Keywords:** fifth metatarsal bone; stress fracture; platelet-rich plasma; football players

Metatarsal fractures are one of the most common foot injuries among athletes.<sup>1</sup> In soccer, they account for ~0.5% of all injuries sustained by elite European footballers with an average period of treatment of about 80 days.<sup>2</sup> This type of fracture is one of the few diagnoses that are based on X-ray, which in most cases allows the diagnosis to be verified.

Treatment of fractures the fifth metatarsal bone among athletes is an actual issue due to the long period of treatment (ie, 8 weeks or more) and a large number of relapses.<sup>3</sup> In the population of athletes, the tactics of treating this type of injuries depend on their localization according to Lawrence and Botte's classification, in which there are 3 zones.<sup>4</sup>

“One of these methods may be the use of platelet-rich plasma (PRP), which contains numerous growth factors.”

Fractures of the first zone are most often treated conservatively with good functional results in any of the categories of the population.<sup>5</sup> Fractures of the second and third zones with conservative treatment tend to be delayed

DOI: 10.1177/19386400211017368. From Sechenov First Moscow State Medical University (Sechenov University), Moscow, Russian Federation (EB, EB, AL); Russian Football Union, Moscow, Russian Federation (EB); Federal Research and Clinical Center of Sports Medicine and Rehabilitation, Federal Medical Biological Agency, Moscow, Russian Federation (EB, AZ); High Performance Sports Laboratory, Moscow Witte University (EB, AL); FC Spartak, Moscow, Russian Federation (GC); FC Zenit, Saint-Petersburg, Russian Federation (VK); Russian Medical Academy of Continuous Professional, Moscow, Russian Federation (EG); Traumatology and Orthopedics Center, Central Clinical Hospital of the Russian Academy of Sciences, Moscow, Russian Federation (EG); Institute of Sport Science, Jerzy Kukuczka Academy of Physical Education, Katowice, Poland (ZW); and A.I. Burnazyan Federal Medical and Biophysical Center, Federal Biomedical Agency of Russia, Moscow, Russian Federation (AL). Address correspondence to: Artemii Lazarev, High Performance Sports Laboratory, Moscow Witte University, Moscow, 115432, Russian Federation; e-mail: lazarevartemii@yandex.ru.

For reprints and permissions queries, please visit SAGE's Web site at <http://www.sagepub.com/journalsPermissions.nav>.

Copyright © 2021 The Author(s)

consolidation and nonunion, therefore the most common way of treating them, especially in the athlete's population, is osteosynthesis using intramedullary screws.<sup>6</sup>

However, surgical treatment does not always lead to positive results. Granata et al<sup>7</sup> reported 7.3% of cases of reoperation among athletes associated with refractoriness for 8 months. With conservative treatment, the basis is the elimination of the load through the use of different types of immobilization boots.<sup>1,8</sup>

Shock wave therapy and electromagnetic fields, calcium and vitamin D are also used.<sup>9-13</sup> The development of new methods of conservative treatment of fractures with minimal treatment periods and the number of relapses is an urgent task for modern professional football medicine.

One of these methods may be the use of platelet-rich plasma (PRP), which contains numerous growth factors. The treatment concept is based on the substitution of growth-inducing substances in tissues with low or absent regeneration capacity (cartilage, tendons) as well as for the induction or further acceleration of growth and regeneration (bone, muscle).<sup>5,14</sup> PRP is emerging as a powerful tool for tissue healing, thanks to the many growth factors contained in platelet alpha-granules. PRP is defined as a blood derivative, where the platelets concentration is above the baseline levels, thus providing a large number of bioactive molecules in physiologic proportions.<sup>15</sup> Activated platelets can release more than 300 molecules that are responsible for the coordination of numerous cell-cell and cell-extracellular matrix (cell-ECM) interactions.<sup>16</sup> The evidence for PRP osteogenic potential has been suggested by several *in vitro* studies, that is, PRP addition in culture medium promoted the proliferation and differentiation of human mesenchymal stem cells (MSCs),<sup>17,18</sup> and the effect of PRP on osteogenic differentiation was also seen on human adipose-derived stem cells (ADSCs).<sup>19</sup> Furthermore, PRP can improve cell chemokinesis and chemotaxis through cytoskeleton

reorganization and accelerate cell migration, thus influencing osteoblast like cells mobility.<sup>20</sup>

PRP is actively used in the treatment of acute and chronic injuries of the musculoskeletal system, in particular muscle injuries, tendinopathies, and arthrosis with positive results.<sup>21,22</sup> Currently, most studies of the effectiveness of PRP in bone damage have been conducted in animals. A study by Lopes et al<sup>23</sup> shows the statistically significant effectiveness of PRP when used in the treatment of fractures of the lower extremities in dogs. Other animal studies also demonstrated the beneficial effect of PRP on healing of both traumatic and osteoporotic fractures was shown.<sup>24,25</sup> There are also limited data on the use of PRP in humans. Memeo et al<sup>26</sup> have obtained excellent results in the repeated surgical treatment of nonunion fractures of the forearm bones in 7 young people using osteosynthesis and PRP. In a study by Malhotra et al<sup>27</sup> using PRP in the treatment of unconsolidated fractures of the long bones, it was possible to consolidate the fractures within 4 months after the start of treatment in more than 85% of cases.

However, we could not find any data on the use of PRP in the treatment of metatarsal bone fractures. Any types of treatment for fractures of the fifth metatarsal bone of zones 2 and 3 in athletes are currently accompanied by relapses and are being treated for a long time. In this regard, the development of protocols for safe and fast conservative treatment of this pathology seems to be an important task. Therefore, we describe the conservative treatment in seven cases of professional football players.

## Case Reports

This study was approved by the local ethics committee of the First Moscow State Medical (Sechenovskiy) University (No. 11-19, 25.07.2019). All participants provided informed consent to participate in the study and publish the data.

The results of the treatment of the fifth metatarsal bone fractures in 7 young

football players of one of the clubs of the Russian Football Premier League are presented. The age varied from 17 to 21 years (mean age was 19 years); mean body height was  $179 \pm 3$  cm, and mean body weight  $73.3 \pm 2$  kg.

All injuries occurred between November 2016 and January 2020 during matches during the competitive season. In all cases, the game was played on artificial turf. In no case there was any discomfort and pain until the moment of injury in the fifth metatarsal bone.

The mechanism of injuries in 5 cases was contact, in 2 contactless, during running with acceleration, sharp local pain appeared in the area of the fifth metatarsal bone.

All football players immediately stopped their sports activities and were immobilized with an orthosis. In all cases, performed radiography confirmed the diagnosis (Figure 1).

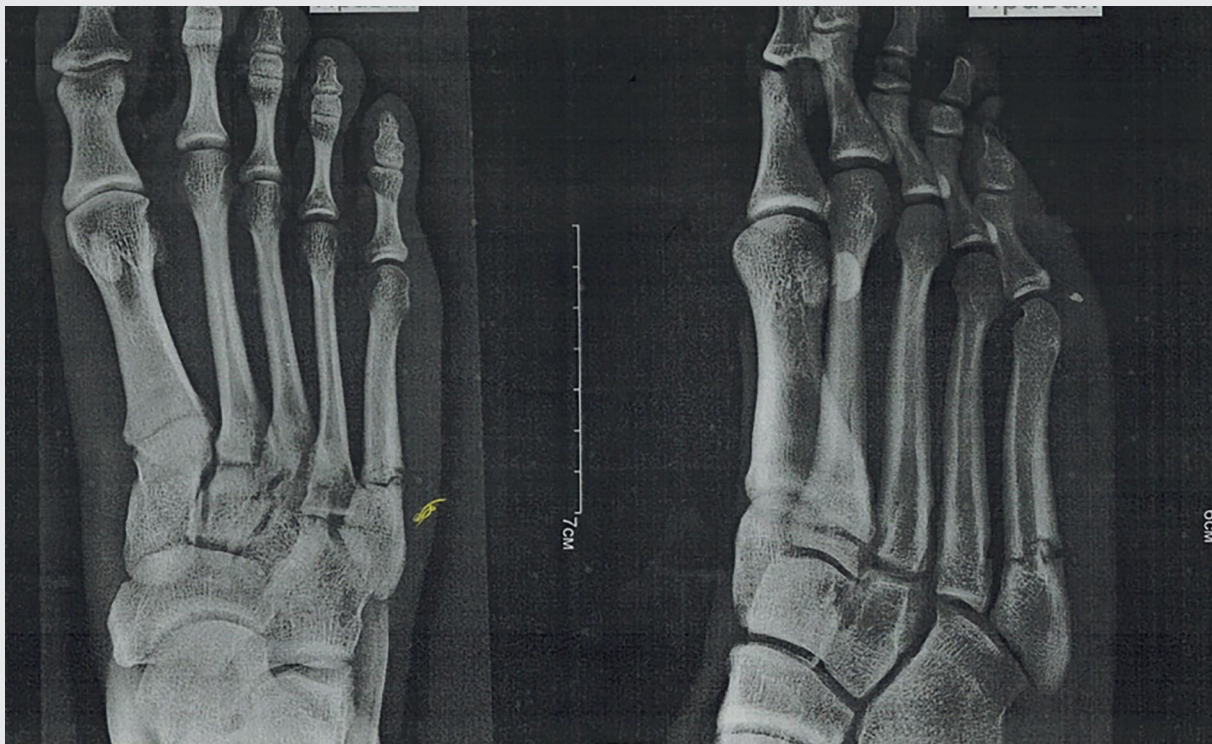
For the first 3 days, the POLICE protocol (protection, optimal loading (rest), ice compression, and elevation) started therapy, including the use of local cyclic compression therapy (Game Ready machine, 7-8 times a day for 20 minutes), compression knitwear, and immobilizing orthosis (MediROM Walker from Medi company). Anti-inflammatory medicines were not used.

From the first day of treatment, calcium was administered at a dose of 1000 mg per day and vitamin D at the dose of 5000 IU for 60 days.

Three days after the injury, the first injection of PRP (4-5 mL) obtained using a BTI centrifuge was performed. To obtain a concentrate, 56 mL of blood taken from the cubital vein was used. The mean platelet count was 698 000/mL. The initial platelet concentration was 209 000/mL. Three injections were performed with an interval of 7 to 10 days. From the third day after the first injection of PRP, low-intensity workouts on a bicycle ergometer of 30 to 40 minutes were performed. From the seventh day of treatment, rehabilitation training began, aimed to the improving blood circulation by using exercises without axial load on the foot.

**Figure 1.**

Radiography confirmed the diagnosis of fifth metatarsal bone fracture.



In all cases, 5 to 7 days after the second injection of PRP, the pain syndrome during normal walking was stopped, but the use of the orthosis continued for 30 days from the moment of injury. Three days after the disappearance of the pain syndrome, low-intensity running work began (10-15 minutes) followed by progression. From the 30th day, all the players started individual work with the ball using boots. The deadline for returning to regular training activities ranged from 43 to 54 days. Return to activity (RTA) was considered as training in the general group of football players without any restrictions.

Control radiography was performed 3 to 5 days before the onset of RTA (Figure 2). During treatment, no allergic reactions or other side effects were identified. Within 6 months after the renewal of RTD, in no case of relapse there was any damage.

## Discussion

It should be noted that all fractures were localized in zones 2 and 3 and have the high risk for delayed consolidation and nonunion. Generally, fractures of the base of metatarsus V are treated conservatively.<sup>5</sup> However, fractures of zones 2 and 3 of the fifth metatarsal bone are at high risk for delayed consolidation and nonunion. Available data of the conservative treatment have reported long-term return to activities and a large number of relapses.<sup>13</sup> Therefore, in most cases, in the group of professional athletes, surgical treatment is currently considered the method of choice for treating of this type of fractures.

With surgical treatment, which is the method of choice in such cases, the average time to RTA ranges from 8 to 12.3 weeks, and repeated injuries can occur in 5% to 30% of cases. Japjec et al<sup>28</sup> reported that the average duration

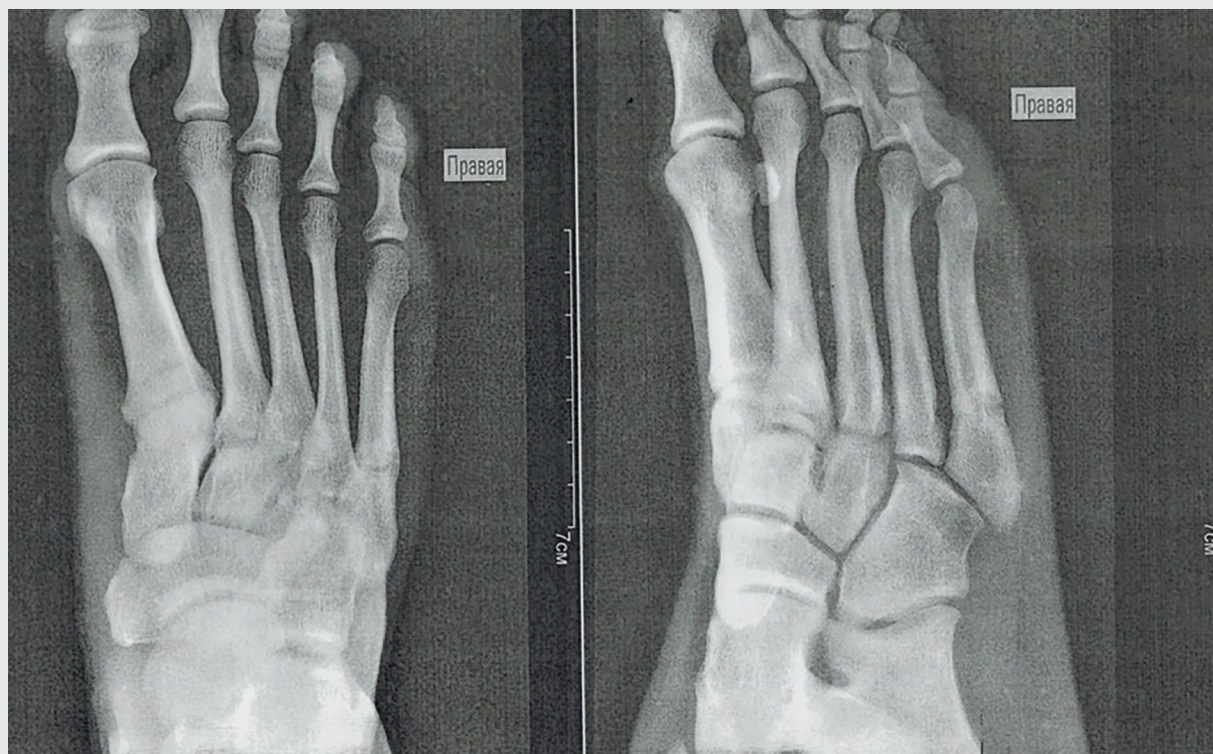
of treatment for most fractures of zones 2 and 3 after osteosynthesis was 8 weeks, and with conservative treatment even after 6 months, more than half of the patients showed no signs of consolidation and remained painful. Hunt et al<sup>6</sup> reported about 21 operated athletes reported with an average recovery time of 12.3 weeks using osteosynthesis with the use of intramedullary screws and only 1 relapsed fracture.

Lareau et al<sup>29</sup> treated 25 National Football League players with Jones fractures with an appropriately placed intramedullary screw and an aggressive rehabilitation protocol. All 9 players who underwent surgery were eligible to return to play in the same season, had an average return to play of 8.7 weeks (range 5.9-13.6 weeks), which was longer than in our study.<sup>29</sup>

O'Malley et al<sup>30</sup> introduced the results of surgical treatment of 10 National Basketball Association players, whose

**Figure 2.**

Radiographs 45 days after conservative treatment using platelet-rich plasma.



average recovery time was 9.8 weeks. Moreover, in 3 cases relapsed fractures occurred.<sup>30</sup> Thus, currently available data show that even surgical treatment of fractures of zones 2 and 3 of the fifth metatarsal bone is characterized by a long rehabilitation period and frequent relapsed fractures. Moreover, in all cases, the duration of the RTA was longer than that obtained in our study (<50 days).

### Limitations and Implications for Future Research

The disadvantages of the study include the small number of participants, as well as the lack of a control group. In this way, the data we obtained of the conservative treatment of this type of injuries with the help of local injections of PRP may be interesting for further studies. In future studies, it would be interesting to

measure pain and function before and after the treatment with PRP through validation scores, such as visual analogue scale and American Orthopaedic Foot and Ankle Society score.

### Conclusion

The development of protocols for safe and fast conservative treatment of the fifth metatarsal bone fractures is an important task. In the cases of conservative treatment of this pathology using PRP in this study, good results were obtained, which consist in shortening the duration of treatment (deadline for returning to regular training activities was 43-50 days) and the absence of relapses (within 6 months of follow-up). Thus, the inclusion of PRP injection in the program of conservative treatment of this type of injury is a good option.

### Declaration of Conflicting Interests

The author(s) declared no potential conflicts of interest with respect to the research, authorship, and/or publication of this article.

### Ethical Approval

This study was approved by the local ethics committee of the First Moscow State Medical (Sechenovskiy) University (No. 11-19, 25.07.2019).

### Informed Consent

All participants provided informed consent to participate in the study and publish the data.

### Trial Registration

Not applicable.

## ORCID iD

Artemii Lazarev  <https://orcid.org/0000-0001-7189-0766> 

## References

- Piyapittayanun P, Mutthakalin K, Anirachakaran A, Kongtharvonskul J. Comparative outcomes of foot cast and short leg cast in pseudo-Jones avulsion fracture: a single blinded randomized controlled trial. *J Foot Ankle Res*. 2019;12:47. doi:10.1186/s13047-019-0359-5
- Ekstrand J, van Dijk CN. Fifth metatarsal fractures among male professional footballers: a potential career-ending disease. *Br J Sports Med*. 2013;47:754-758.
- Cheung CN, Lui TH. Proximal fifth metatarsal fractures: anatomy, classification, treatment and complications. *Arch Trauma Res*. 2016;5:e33298. doi:10.5812/atr.33298
- Lawrence SJ, Botte MJ. Jones' Fractures and related fractures of the proximal fifth metatarsal. *Foot Ankle Int*. 1993;14:358-365.
- Tittel K, Schmidt P. Fracture of the base of metatarsus V—conservative or operative treatment? [in German]. *Unfallchirurgie*. 1984;10:207-10.
- Hunt KJ, Anderson RB. Treatment of Jones fracture nonunions and refractures in the elite athlete: outcomes of intramedullary screw fixation with bone grafting. *Am J Sports Med*. 2011;39:1948-1954.
- Granata JD, Berlet GC, Philbin TM, Jones G, Kaeding CC, Peterson KS. Failed surgical management of acute proximal fifth metatarsal (Jones) fractures: a retrospective case series and literature review. *Foot Ankle Spec*. 2015;8:454-459. doi:10.1177/1938640015592836
- Janssen E, Rijpsma D. BET 1: functional treatment is non-inferior to below the knee cast in adults with acute closed proximal fifth metatarsal fractures. *Emerg Med J*. 2019;36:319-320. doi:10.1136/emered-2019-208644.1
- Alvarez RG, Cincere B, Channappa C, et al. Extracorporeal shock wave treatment of non-or delayed union of proximal metatarsal fractures. *Foot Ankle Int*. 2011;32:746-754. doi:10.3113/FAI.2011.0746
- Clutton J, Perera A. Vitamin D insufficiency and deficiency in patients with fractures of the fifth metatarsal. *Foot (Ednib)*. 2016;27:50-52. doi:10.1016/j.foot.2015.08.005
- Shindle MK, Endo Y, Warren RF, et al. Stress fractures about the tibia, foot, and ankle. *J Am Acad Orthop Surg*. 2012;20:167-176. doi:10.5435/JAAOS-20-03-167
- Streit A, Watson BC, Granata JD, et al. Effect on clinical outcome and growth factor synthesis with adjunctive use of pulsed electromagnetic fields for fifth metatarsal nonunion fracture: a double-blind randomized study. *Foot Ankle Int*. 2016;37:919-923. doi:10.1177/1071100716652621
- Thevendran G, Deol RS, Calder JDF. Fifth metatarsal fractures in the athlete: evidence for management. *Foot Ankle Clin*. 2013;18:237-254. doi:10.1016/j.fcl.2013.02.005
- Leitner L, Gruber G, Lohberger B, Kaltenecker H, Leithner A, Sadoghi P. Clinical administration of platelet-rich plasma and growth factors to the musculoskeletal system [in German]. *Orthopade*. 2019;48:105-116. doi:10.1007/s00132-018-3643-3
- Di Matteo B, Filardo G, Kon E, Marcacci M. Platelet-rich plasma: evidence for the treatment of patellar and Achilles tendinopathy—a systematic review. *Musculoskelet Surg*. 2015;99:1-9. doi:10.1007/s12306-014-0340-1
- Rodriguez IA, Growney Kalaf EA, Bowlin GL, Sell SA. Platelet-rich plasma in bone regeneration: Engineering the delivery for improved clinical efficacy. *Biomed Res Int*. 2014;2014:392398. doi:10.1155/2014/392398
- El Backly RM, Zaky SH, Muraglia A, et al. A platelet-rich plasma-based membrane as a periosteal substitute with enhanced osteogenic and angiogenic properties: a new concept for bone repair. *Tissue Eng Part A*. 2013;19:152-165. doi:10.1089/ten.TEA.2012.0357
- Kasten P, Vogel J, Luginbühl R, et al. Influence of platelet-rich plasma on osteogenic differentiation of mesenchymal stem cells and ectopic bone formation in calcium phosphate ceramics. *Cells Tissues Organs*. 2006;183:68-79. doi:10.1159/000095511
- McLaughlin M, Gagnet P, Cunningham E, et al. Allogeneic platelet releasate preparations derived via a novel rapid thrombin activation process promote rapid growth and increased BMP-2 and BMP-4 expression in human adipose-derived stem Cells. *Stem Cells Int*. 2016;2016:7183734. doi:10.1155/2016/7183734
- Casati L, Celotti F, Negri-Cesi P, Sacchi MC, Castanoy P, Colciago A. Platelet derived growth factor (PDGF) contained in platelet rich plasma (PRP) stimulates migration of osteoblasts by reorganizing actin cytoskeleton. *Cell Adh Migr*. 2014;8:595-602. doi:10.4161/19336918.2014.972785
- Grambart ST. Sports Medicine and platelet-rich plasma: nonsurgical therapy. *Clin Podiatr Med Surg*. 2015;32:99-107.
- Laudy ABM, Bakker EWP, Rekers M, Moen MH. Efficacy of platelet-rich plasma injections in osteoarthritis of the knee: a systematic review and meta-analysis. *Br J Sports Med*. 2015;49:657-672.
- López S, Vilar JM, Sopena JJ, et al. Assessment of the efficacy of platelet-rich plasma in the treatment of traumatic canine fractures. *Int J Mol Sci*. 2019;20:1075. doi:10.3390/ijms20051075
- Chen L, Yang X, Huang G, et al. Platelet-rich plasma promotes healing of osteoporotic fractures. *Orthopedics*. 2013;36:e687-e694.
- Simman R, Hoffmann A, Bohinc RJ, Peterson WC, Russ AJ. Role of platelet-rich plasma in acceleration of bone fracture healing. *Ann Plast Surg*. 2008;61:337-344.
- Memeo A, Verdoni F, De Bartolomeo O, Albisetti W, Pedretti L. A new way to treat forearm post-traumatic non-union in young patients with intramedullary nailing and platelet-rich plasma. *Injury*. 2014;45:418-423. doi:10.1016/j.injury.2013.09.021
- Malhotra R, Kumar V, Garg B, et al. Role of autologous platelet-rich plasma in treatment of long-bone nonunions: a prospective study. *Musculoskelet Surg*. 2015;99:243-248. doi:10.1007/s12306-015-0378-8
- Japjec M, Starešinić M, Starjački M, Žgaljardić I, Štivičić J, Šebečić B. Treatment of proximal fifth metatarsal bone fractures in athletes. *Injury*. 2015;46(suppl 6):S134-S136.
- Lareau CR, Hsu AR, Anderson RB. Return to play in national football league players after operative Jones fracture treatment. *Foot Ankle Int*. 2016;37:8-16. doi:10.1177/1071100715603983
- O'Malley M, Desandis B, Allen A, Levitsky M, O'Malley Q, Williams R. Operative treatment of fifth metatarsal Jones fractures (zones II and III) in the NBA. *Foot Ankle Int*. 2016;37:488-500.